

# Fracture of Uncemented Revision Femoral Stems in three Arthroplasty Patients: A Case Series with three different brands.

Rajiv Merchant<sup>1</sup>, Ian Kelly<sup>1</sup>, John Quinlan<sup>1</sup>

## What to Learn from this Article?

Causes and management of Fractured revision femoral stems

### Abstract

**Introduction:** Fracture of stems in primary total hip arthroplasty is a known complication and has been attributed to varus positioning, excessive weight of the patient, resorption of the femoral calcar and failure of the cement mantle. Fractures in uncemented revision femoral stems are rare and are attributed to reduction in proximal support either in the form of bone loss or an extended trochanteric osteotomy [ETO] against a distally well-fixed stem. Also, undersized stems and high BMI to increase the risk of stem fracture.

**Case Report:** We report 3 cases of uncemented revision stem fractures. Case 1 is a 77 year old male, Case 2 is a 71-year-old female, case 3 an 82-year-old male. All three patients had significant proximal femoral osteolysis. All three had an extended trochanteric osteotomy for the revision surgery. The hips had remained in-situ for 4, 2 and 5 years respectively prior to fracture.

**Conclusion:** When planning complex revision cases involving long uncemented stems, attention should be given to the above-mentioned variables. ETO non-union and proximal bone loss play an important role in stem fractures. Stem failure can occur irrespective of the make, and factors such as adequate stem size and good diaphyseal fit are non negotiable.

**Keywords:** Arthroplasty, Replacement, Hip; Stem fracture; Revision arthroplasty.

### Introduction

Fracture of stems in primary cemented hip arthroplasty is a known complication and has been attributed to varus positioning, excessive weight of the patient, resorption of the femoral calcar and failure of the cement mantle.[1] Fractures in uncemented revision femoral stems are rare.[2, 3] Busch et al.[3] attribute this to reduction in proximal support either in the form of bone loss or an extended trochanteric osteotomy

[ETO] against a distally well-fixed stem. Thigh pain, late osteolysis, aseptic loosening and lack of osseous integration are some other complications of uncemented femoral components. [2] Reconstruction of the femoral offset during revision hip arthroplasty is important for maintaining the stability of the joint.[4] This coupled with the absence of adequate proximal support in aseptic loosening or ETO can lead to increase in implant stresses when the stem is well fixed distally. [5, 6]

Access this article online	
Quick Response Code	Website: www.jocr.co.in
	DOI: 10.13107/jocr.2250-0685.215

### Author's Photo Gallery



Dr. Rajiv Merchant



Dr. Ian Kelly



Dr. John Quinlan

<sup>1</sup>Department of Orthopaedic, Waterford Regional Hospital, Waterford, Ireland.

Address of Correspondence

Dr. Rajiv Merchant, James Connolly Memorial Hospital, Blanchardstown, Dublin 15, Ireland.

Email: rajivmerchant@rcsi.ie

Copyright © 2014 by Journal of Orthopaedic Case Reports

Journal of Orthopaedic Case Reports | pISSN 2250-0685 | eISSN 2321-3817 | Available on www.jocr.co.in | doi:10.13107/jocr.2250-0685.215

This is an Open Access article distributed under the terms of the Creative Commons Attribution Non-Commercial License (<http://creativecommons.org/licenses/by-nc/3.0/>) which permits unrestricted non-commercial use, distribution, and reproduction in any medium, provided the original work is properly cited.



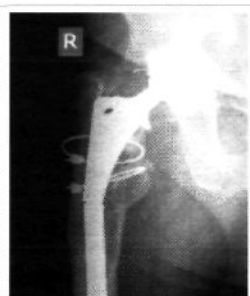

Figure 1: X-ray showing fractured stem. Note the poor proximal bone support. The visible clips were present from the primary surgery and were used to tag the abductor repair

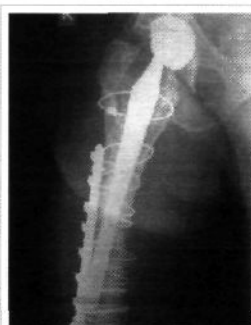

Figure 2: Case 1: Postoperative radiograph showing a cable plate applied to support a distal peri-prosthetic fracture

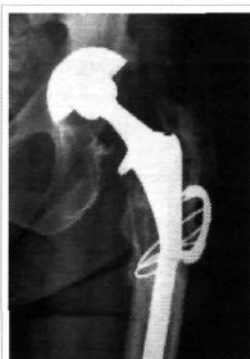

Figure 3: Case 2: Radiograph showing fracture through an Echelon™ stem just distal to the extended trochanteric osteotomy site

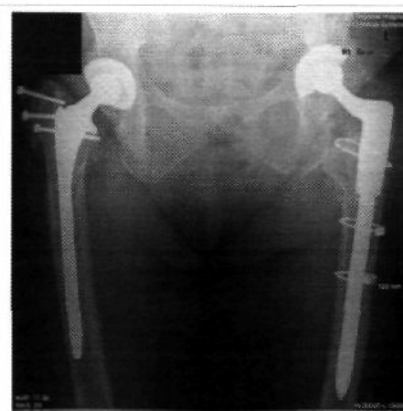

Figure 4: Case 2: Post-operative follow-up radiograph

Smaller stems in particular are at a greater risk of fracture as the bending moment of a homogenous cylinder is inversely proportional to product of the young's modulus of elasticity and its area moment of inertia. [7]

We report 3 cases of uncemented revision stem fractures. We summarize the variables affecting our patients especially regarding poor proximal support and small size of stems. Subsequent revision is described.

## Case Report

### Case 1

A 77-year-old gentleman had a right total hip arthroplasty done in 1998 and subsequently underwent a revision in 2004 of both the femoral and acetabular components for instability and failed prosthesis. An extended trochanteric osteotomy was used to extract the femoral stem which was replaced with a cementless bowed Solution™ stem [DePuy inc. Warsaw, Indiana] sized 13.5 mm. The trochanteric osteotomy was reattached with two Dall-Miles™ cables. 4 years later with he presented the emergency department with deteriorating groin pain in the absence of trauma. His radiograph [X-Ray 1] showed an extensive proximal osteolysis and a transverse fracture at the junction of the proximal and middle third of the stem. His re-revision surgery consisted of a proximal femoral osteotomy to remove proximal end of the stem with care. The distal portion was removed using osteotomes, wires and trephine. The stem was replaced with a 16mm Reef™ prosthesis [DePuy, Warsaw, Indian]. The reaming caused a Vancouver C type periprosthetic fracture and was treated with a Dall-Miles cable plate. The ETO was repaired using Dall-Miles cables [X-Ray 2]. The patient had an uneventful course to recovery. The post operative xray was taken at the patients last outpatient visit prior to discharge at a time period of 2 years post surgery. Patient was ambulating with a walking stick.

### Case 2

A 71-year-old lady had had a left total hip replacement, which had been revised in 2007 for aseptic loosening. Components used were a 12mm Echelon™ Stem

[Smith and Nephew, Memphis, Tennessee]. In 2008 she presented with repeated dislocation and underwent further revision with change of liner and exchange of head. In 2009 she presented for routine outpatient review for osteoarthritis of the left knee and incidentally complained of left hip and groin pain for the past month. Her radiograph [X-Ray 3] showed a fracture of the Echelon™ stem with an obvious non-union of the ETO and severe osteolysis under the stem collar. At the time of surgery the trochanteric fragment simply lifted off the femur once the Dall-Miles clamp was removed. A Dall-Miles cable was inserted distal to the claw and a proximal osteotomy was performed to reveal the upper 4 cm of the stem. A size 12.5mm curved osteotome was used carefully throughout the stem to free it up and then using vice-grips and a series of punches the stem was extracted. As the distal cement plug was still present from the primary surgery an intramedullary wire was then passed down through it and 8mm to 8.5 mm reamers were used to remove it. A Mooreland hook was then used to retrieve cement and the canal was further reamed to 14mm. The stem was replaced with a Restoration™ Cone bowed stem [Stryker, Mahwah, New Jersey]. The femoral osteotomy was then reattached using Dall-Miles cables. This patient continues to do well on ongoing follow-up [X-Ray 4].

### Case 3

An 82 year old presented to the outpatients departs with worsening difficulty while walking, increasing stiffness and pain

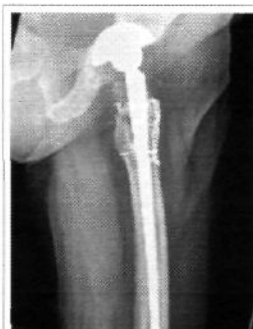

Figure 5: Case 3: Full-length radiograph showing fracture through distal third portion of stem

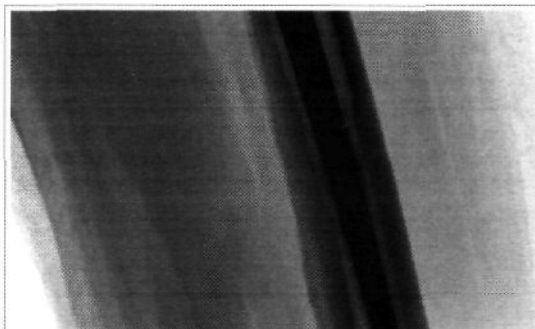


Figure 6: Case 3: Magnified view of the same radiograph showing the fractured stem



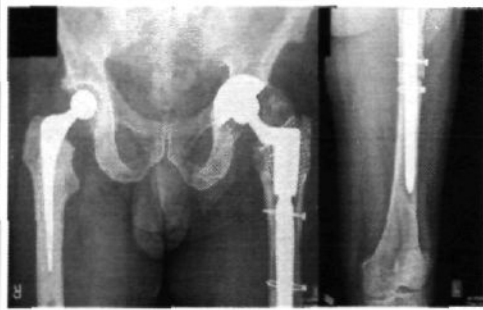

Figure 7: Case 3: Magnified view of the same radiograph showing the fractured stem

Table 1: Summary of variables affecting the cases

Sex	Case 1	Case 2	Case 3
	Male	Female	Male
Age	77	71	82
Time in Situ to Fracture	4 years	1 year 11 months	5 years
Trochanteric Osteotomy	Yes	Yes	Yes
Proximal Femoral Osteolysis	Significant	Significant	Significant
Stem Diameter	13.5mm	12mm	14mm
Patient Weight	107Kg	80Kg	80Kg

in his left hip for 1 month. He had trouble flexing the hip and was focally tender over the greater trochanter and immediately distal to it. He had had a loosening of a left total hip replacement in 2003 that required revision. He underwent revision of the acetabulum component with bone grafting of acetabulum and proximal femur. In 2007 he then underwent a revision of stem through a posterior approach on this occasion. The femur was reamed to 13mm and a Restoration™ stem [Stryker, Mahwah, New Jersey] was inserted. In 2012 his radiograph [X-Ray 5 and 6] showed a fracture at the femoral stem immediately proximal to the femoral isthmus. During his surgery the hip joint was opened through an anterolateral approach. An extended trochanteric osteotomy was performed. The proximal stem was removed. The distal stem was well fixed and there was a prolonged and difficult trephining over the stem. The stem was eventually removed requiring a vertical cortical breach from the long trephine in distal femur. A 22mm distal and 23mm x 75mm proximal body ReClaim™ modular stem [DePuy inc. Warsaw, Indiana] was inserted. The acetabular component was left intact. The osteotomy was reattached with two circlage cables. He has had an uneventful course of recovery and remains pain free to date with no complaints [X-Ray 7 and 8].

**Discussion**

Femoral metaphyseal bone loss and multiple hip surgery can make revision arthroplasty with cement challenging. [8-9] Distal diaphyseal fixation achieved in extensively porous coated stems used in uncemented revision, help bypass this problem.[11] These implants give a tight diaphyseal fit and ensure good stability to reduce the likelihood of mechanical failure.[12] However, in these distally well fixed revision stems, finite element analysis done by Busch et al.[3] showed that a stress riser arose at the distal end of the ETO and coincided with all 5 of their fractured uncemented porous coated stems. They also found that undersized stems, high BMI (>30) poor proximal bone support, smaller diameter stems [<13.5mm] and extended trochanteric osteotomy were more prone to fracture. As can be seen from table 1. majority of these variables pertaining to the cases above are similar. In case 1 with Solution™ stem [DePuy inc. Warsaw, Indiana] the fracture was at the junction between proximal and middle thirds, as the patient had been symptomatic but ambulatory for 4 months prior to diagnosis we attribute its failure to cantilever forces occurring at the said junction. Patient weight (107kg) may have also been a contributory factor. In case 2 with Echelon™ Stem [Smith and Nephew, Memphis, Tennessee] the proximal bone support was compromised by a

non-union of the ETO. The stem fracture was at the distal end of the ETO non union keeping with the authors impression that it would lead to the earlier fracturing of the stem relative to the other two cases. The mechanism of failure as in the previous case would be cantilever forces generated by a weak proximal support. In case 3 Restoration™ stem [Stryker, Mahwah, New Jersey] the stem fracture was distal in comparison to the

previous two cases, we believe that the stress riser was due to the distal fixation rather than a weak proximal support. What is notable is that in all cases there was an absence of trauma and all patients presented with chronic complaints.

Stress risers in extensively porous coated stems are derived from un-united extended trochanteric osteotomy (ETO), proximal bone loss and periprosthetic fractures. [5] In the case of an un-united ETO the stress rise may be double within a revision component. Proximal bone deficiency can be supported by cancellous impaction allografting [13] or a strut allograft on the tension side of the femur. [3] Impaction allografting supplements the proximomedial bone stock (Calcar) and may help decrease cantilever forces. Unfortunately this is not without complication as higher hoop stresses increase the risk of fracture. [13] The authors did not attempt to augment the proximal bone stock by this method for the same reason. Augmenting the tension side of the femoral ETO with a strut allograft and securing it with proximal and distal cables was an option, unfortunately this was neither available nor routine practice in our unit. The authors felt that the larger stem sizes were adequate in the three cases.

The main principle of revision surgery is to achieve a stable fixation of the femoral component. The diaphyseal portion of the femur offers adequate bone stock and can be used for the same as a tight fit also offers good rotation stability. Failure generally tends to occur when the canal filling is inadequate. [12].

Adequate implants and tools must be available during revision [14, 15] as stem extraction can be lengthy and difficult as it was in case 3. Lastly when revising with modular stems one must note that most stems fail at the junction of the stem taper. This is due to reducing cross sectional area of the stem taper, it coinciding with the ETO and fretting corrosion that may affect the junction. [16] Therefore care should be taken during implanting

**Conclusion**

When planning complex revision cases involving long uncemented stems, attention should be given to the above-mentioned variables.

**Clinical Message**

Stem fractures are rare and usually present in an insidious fashion. X-rays of patients, which have the above, mentioned risk factors should be closely scrutinized as early diagnosis of impending failure can make revision surgery less difficult.



## References

1. Andriacchi TP, Galante JO, Belytschko TB, Hampton S. A stress analysis of the femoral stem in total hip prostheses. *J Bone Joint Surg Am.* 1976 Jul;58[5]:618-24.
2. Lawrence JM, Engh CA, Macalino GE, Lauro GR. Outcome of revision hip arthroplasty done without cement. *J Bone Joint Surg Am.* 1994 Jul;76[7]:965-73.
3. Busch CA, Charles MN, Haydon CM, Bourne RB, Rorabeck CH, Macdonald SJ, et al. Fractures of distally-fixed femoral stems after revision arthroplasty. *J Bone Joint Surg Br.* 2005 Oct;87[10]:1333-6.
4. Cheal EJ, Spector M, Hayes WC. Role of loads and prosthesis material properties on the mechanics of the proximal femur after total hip arthroplasty. *J Orthop Res.* 1992 May;10[3]:405-22.
5. Crowninshield RD, Maloney WJ, Wentz DH, Levine DL. The role of proximal femoral support in stress development within hip prostheses. *Clin Orthop Relat Res.* 2004 Mar;420:176-80.
6. Heller MO, Mehta M, Taylor WR, Kim DY, Speirs A, Duda GN, et al. Influence of prosthesis design and implantation technique on implant stresses after cementless revision THR. *J Orthop Surg Res.* 2011;6:20.
7. Keaveny TM, Bartel DL. Mechanical consequences of bone ingrowth in a hip prosthesis inserted without cement. *J Bone Joint Surg Am* 1995;77:911.
8. Allan DG, Lavoie GJ, McDonald S, Oakeshott R, Gross AE. Proximal femoral allografts in revision hip arthroplasty. *J Bone Joint Surg Br.* 1991 Mar;73[2]:235-40.
9. Head WC, Malinin TI, Berklacich F. Freeze-dried proximal femur allografts in revision total hip arthroplasty. A preliminary report. *Clinical Orthopaedics and Related Research.* 1987 //;No. 215:109-21.
10. Martin WR, Sutherland CJ. Complications of proximal femoral allografts in revision total hip arthroplasty. *Clin Orthop Relat Res.* 1993 Oct[295]:161-7.
11. Lawrence JM, Engh CA, Macalino GE. Revision total hip arthroplasty. Long-term results without cement. *Orthop Clin North Am.* 1993 Oct;24[4]:635-44.
12. Krishnamurthy AB, MacDonald SJ, Paprosky WG. 5- to 13-year follow-up study on cementless femoral components in revision surgery. *J Arthroplasty.* 1997 Dec;12[8]:839-47.
13. Morgan HD, McCallister W, Cho MS, et al. Impaction allografting for femoral component revision: clinical update. *Clin Orthop Relat Res* 2004:160.
14. Landa J, Benke M, Dayan A, Pereira G, Di Cesare PE. Fracture of fully coated echelon femoral stems in revision total hip arthroplasty. *J Arthroplasty.* 2009 Feb;24(2):322 e13-8.
15. Lu HC, Lin CL, Chang CW, Lai KA. Fracture of VerSys fully bead-coated long femoral stems: report on four fractures in 41 hips. *The Kaohsiung journal of medical sciences.* 2012 Jun;28(6):345-9.
16. Lakstein D, Eliaz N, Levi O, Backstein D, Kosashvili Y, Safir O, et al. Fracture of cementless femoral stems at the mid-stem junction in modular revision hip arthroplasty systems. *J Bone Joint Surg Am.* 2011 Jan 5;93(1):57-65.

Conflict of Interest: Nil  
Source of Support: None

### How to Cite this Article

Merchant R, Kelly I, John Quinlan J. Fracture of Uncemented Revision Femoral Stems in three Arthroplasty Patients: A Case Series with three different brands. *Journal of Orthopaedic Case Reports* 2014 Oct-Dec;4(4): 12-15

